

# Active Cardiac Model and its Application on Structure Revealing from Fetal Ultrasound Sequence

Manikandan. M<sup>1</sup>, Prof.S.Prabakar<sup>2</sup>

<sup>1</sup>Research Scholar (PG), Department of ECE, Kathir College of Engineering, Coimbatore, India

<sup>2</sup> Associate Professor, Department of ECE, Kathir College of Engineering, Coimbatore, India

E-mail- maniece022@gmail.com

**Abstract**— A fetal cardiac defect is one of the most high risk fetal congenital anomalies and is also one of the primary reasons for the death of the newborn. The fetal heart structure detection from is important for diagnosis of the fetuses which is difficult due to the small size of the initial level of the fetuses. Fetal heart abnormalities are the most common congenital anomalies and also the leading cause infant mortality related to birth defects. A novel method is proposed for the detection of fetal heart structure from ultrasound images. An initial pre-processing is done for removal of noise and enhances the noiseless images. Level set method is applied to the sequence of fetal ultrasound images to segment the region of interest. However to observe the outflows tracts successfully requires special training in fetal cardiac image is known as an active appearance model, which is used to designed and trained using ultrasound sequences which efficiently extract the cardiac structure from an input image. The developing methods are efficient which has been verified, validated and appreciated by the doctors.

**Keywords**— Cardiac Defects, Ultrasound Image, Level Set, Appearance Model, Cardiac Structure.

## INTRODUCTION

Fetal cardiac defects are one of the most high risk congenital cardiac defects. Approximately 1% of the fetuses unnatural from congenital cardiac defects. This is also the most important reason of the death of the new born baby. The difficult anatomy and dynamics of the fetal heart put together it a challenging organ to image. More complex and investigation methods are essential to obtain diagnostic information concerning fetal cardiac anatomy and functions.

Congenital heart disease (CHD) is a leading root of infant mortality with a predictable incidence of about 4-13 per 1000 live births. Despite the well accepted utility of a four chamber view. We should be aware of potential diagnostic pitfalls that can prevent timely recognition of CHD. It technically routine views of the outflow tracts should be attempted as part of a comprehensive basic cardiac inspection. Evaluation of outflow tracts can expand the detection rates for major cardiac irregularity above those achievable by the four chamber view alone.

An extended basic examination minimally requires that ordinary great vessels are more or less identical in size and that they cross each other. The basic cardiac selection examination relies on a four chamber view of the fetal heart. This view should not be mistaken for a simple chamber count because it involves a careful evaluation of detailed criteria. To help identification of fetal heart is this paper we proposed a method for detection of fetal cardiac structure in the four chamber view.

The remaining of this paper is prepared as follows section 2 will describes the input ultrasound image sequences is first converted into the gray scale image. The next level is filtered the image sequences for the higher level process. The sequences of images will segmented by the best segmentation method and are compare with the active appearance model to extract the four chamber identification of the fetal heart is made. Section 3 describes the experimental results of the developed method and conclusion is drawn in Section 4.

Highly skilled operations and time consuming for the doctors is required in the fetal heart diagnosis. From this sense many methods are proposed and to help the diagnosis of the fetal heart. Using the level set snake based to measure the size of the septal defects in image based on the fast marching method by Lasseg et al. To applied the self organizing map to fetal heart segment to obtain the heart structure is used Siqueira. Irving Dindoyal proposed a more improved level set algorithm. Segment four chambers of fetal heart by introducing the shape prior. Bhagwati Charan Patel used an adaptive K-Means clustering algorithm for detection of micro calcifications for the breast image segmentation.

Pedro F Felzenszwalb developed an object detection system. This object was mixture of multiscale deformable part model of highly variable objects. A discriminative procedure used to train these models by bounding boxes for the objects in a set of images. An efficient direct optimization approach that simultaneously matches shape and texture result in this method is rapid, accurate and robust

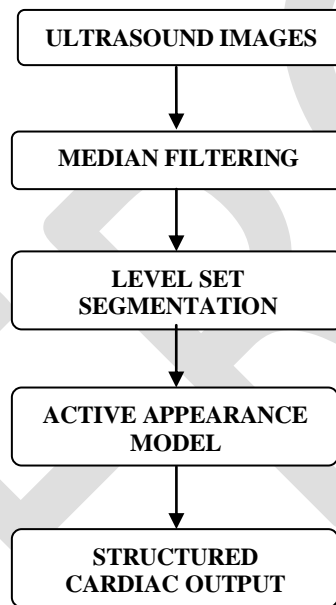
was developed Cootes. The Rayleigh distribution is used to model the speckle and adopt the robust maximum likelihood estimation method was developed by Aysal and his teams.

To extract the boundaries of the four chamber activities based on geometric models based automatic segmentation was introduced by Antunes. The performance of this technique is compared with three alternative level set functions, the break point segmentation and the contours are developed by a pediatrician. Yagel and Cohen are to view the cardiac activities in 3D/4D fetal echocardiography. Compare all this methods and we proposed the following described method.

## II MATERIALS AND METHODS

The pioneering method is proposed for the detection of fetal cardiac structure from ultrasound images a preliminary preprocessing is done, the eliminate noise and enhance the images using median filtering. An effective Level set algorithm is then applied to the segments the region of interest (ROI). To end with an active appearance model is proposed to identify the structure of the fetal.

In this part, the proposed technique is described in detail and the flowchart is shown as Figure 1.



**Figure 1: Proposed Technique**

### *1. Pre-processing:-*

During last several decades ultrasound imaging become widely used and safe medical diagnostic method. Ultrasound is an oscillating sound pressures wave with a frequency greater than the upper limit of the human being hearing range. Ultrasound is used in many special fields. Ultrasonic procedures are used to discover objects and measures distances. Ultrasonic imaging is used both veterinary medicine and human medicine.

Ultrasound can be used for medical imaging, detection measurements cleaning. Human can hear the ultrasound ranges up to 20 KHz but the animals can detect the frequency ranges beyond 100 KHz, possibly up to 200 KHz. Ultrasound based diagnostic medical imaging technique and to imagine muscles, tendons and many inner organs to detain their size, arrangement and any pathological lesions with actual tomography images. Ultrasound is used to imagine fetuses during usual and emergency parental care. As at present useful in the medical fields properly performed ultrasound pose no known risk to the patients.

### *A). Conversion of grayscale:-*

Before preprocessing the input images are converted into gray scale images to enable the application of filter. The true color ultrasound images in RGB are converted grayscale intensity image by eliminating the hue and saturation information while retaining the luminance.

### B). Median Filtering:-

The Median filtering is a nonlinear digital filtering technique often used to remove noise.

$$\text{Median}[A(x) + B(x)] = \text{Median}[A(x)] + \text{Median}[B(x)] \quad (1)$$

It is widely used as it is very effective at removing noise while preserving edges. It is particularly effective at removing 'salt and pepper' type noise. The median filter works by moving through the image pixel by pixel, replacing each value with the median value of adjacent pixels. The prototype of neighbors is called the window, which slides, pixel through pixel more than the complete image pixel, image. The median is designed by first sorting all the pixel values from the window into mathematical order, and then replacing the pixel being measured with the center pixel value. Such noise reduction is a typically preprocessing step to get better the results of later processing.

Median filtering is very widely used in digital image processing because; under definite circumstances it preserves edges while removing noise. In median filtering, the neighboring pixels are ranked according to brightness and the median value becomes the new value for the central pixel. The median is, in a sense, a more robust "average" than the mean, as it is not affected by outliers. Since the output pixel value is one of the neighboring values, new "unrealistic" values are not formed near edges. Since edges are simply despoiled, median filters can be applied repetitively, if essential.

### 2. Segmentation:

Segmentation is defined as partitioning portions of an image. It adds structure to a raw image. In the case of medicine, this can involve identifying which portions of an image is the tumor, or separating white matter from grey matter in a brain scan. This report presents a simple implementation of an active contour method using level sets and demonstrates this method's abilities. This report will present the formulation of the level set method and issues in numerically implementing the problem. It will then follow with results of the implementation and close with areas for further improvements.

The segmentation problem reduces to finding curve to enclose regions of interest. Intuitively, the model and the curves directly using control points. Data structures for the curve would then need to be updated as well. If control points are too close together, how should they be merged there are solutions to these difficulties. However, these issues can all be all deviated using the level set method.

In mathematics, a level set of a real-valued function of  $n$  real variables  $f$  is a set of the form

$$L_c(f) = \{(x_1, \dots, x_n) | f(x_1, \dots, x_n) = c\} \quad (2)$$

That is, a given constant value  $c$  a set where the function takes.

When the number of variables is two a curve is generically a level set called a level curve, curve line or isoline. So a level curve is the set of all real-valued solutions of an equation in two variables  $x_1$  and  $x_2$ . When  $n = 3$  a level set is called a level surface and for higher values of  $n$  the level set is a level hyper surface. So a level surface is the set of all real-valued roots of an equation in three variables  $x_1$ ,  $x_2$  and  $x_3$ , and a level hyper surface is the set of all real-valued roots of an equation in  $n$  variables.

### 3. Active appearance model:-

In the field of medical image processing there is arise a need to fit the shape of an object. If the object is rigid then matching of such model is not necessary on the other hand if the object is non-rigid the matching is needed. Such a matching is carry out by Active Appearance Model (AAM) is used to match the defined set of points to images using their texture information as the matching criteria. In object recognition application, accurate object alignment has determinative effect. Active appearance model is one of the most studied methods for accurate locating objects.

An active appearance model is a computer vision algorithm for matching a statistical model of object shape and appearance to a new image. They are built at some stage in a preparation phase. A images set, together with coordinates of landmarks that appear in all of the images, is provided to the training controller. The draw near is widely used for identical and tracking faces and for medical image analysis. The algorithm uses the dissimilarity between the current approximation of appearance and the target image to drive an optimization method. By taking benefit of the least squares techniques, it can counterpart to new images very rapidly. It is related to the active shape model (ASM). One disadvantage of ASM is that it only uses shape constraints and does not take advantage of all the available information in the texture crossways the goal object. This can be model by means of an AAM.

Let the optimal training set for the automated segmentation of short axis left ventricular magnetic resonance (MR) imaging studies in clinical practice based on active appearance model. The segmentation accuracy by varying the size and composition of the training set. The accuracy was assessed using the degree of similarity and the difference in ejection fraction between automatically detected and manually drawn contours. Including more images in the training set results in a better accuracy of the detected contours, with optimum results achieved when including 180 images in the training set.

Using AAM-based contour detection with a mixed model of 80% normal-20% pathologic images does provide good segmentation accuracy in clinical routine. Finally, it is essential to define different AAM models for different vendors of MRI systems.

### III RESULTS AND DISCUSSION

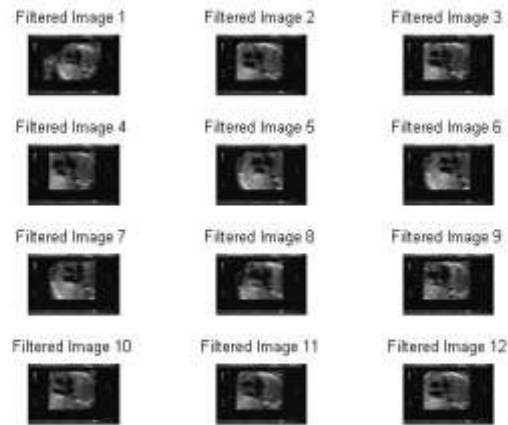
In this proposed method the input image sequence is obtained from the ultrasound sequence. Ultrasound image sequences are the continuous moving frames. First and foremost thing is divide the successive frames per seconds in to image sequence. This sequence of images is effortless to process for our constraint. From this multiple image sequences we prefer twelve images as the suitable images and convert those images into gray scale image then removing unwanted noise which is present in the input image by the aid of median filter. Next is to noiseless images will resized. From that sequence of image choose one better image for the level set segmentation

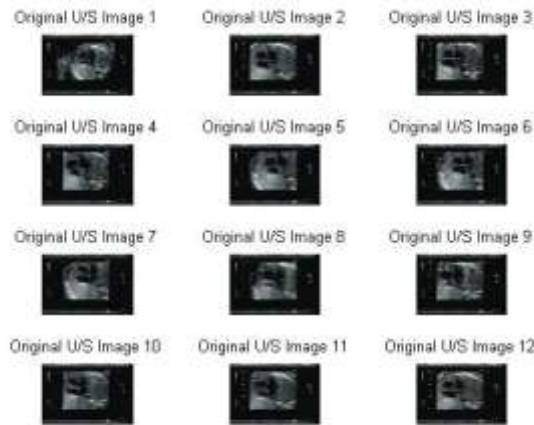

Figure 2: Input Image sequences




Figure 3: Gray scale image sequences




**Figure 4: Filtered image sequences**



**Figure 5: Resized image sequences**



**Figure 6: Level set iteration Image**



**Figure 7: Segmented ROI**

## CONCLUSION

A novel and efficient method for automated detection of fetal cardiac structure has been proposed in this paper. After initial preprocessing, the region of interest has been successfully segmented. The final fetal cardiac structure detection is being implemented by active appearance model.

## REFERENCE:

- [1]. Yinhui Deng Yuan Wang, China and Ping Chen, China Automated Detection of Fetal Cardiac Structure from First-trimester Ultrasound Sequences. 3rd International Conference on Biomedical Engineering and Informatics in 2010
- [2]. B. Cohen I.Dinstein, "New maximum likelihood motion estimation schemes for noisy ultrasound images," Pattern Recognition, vol.35, pp. 455–463 in 2002 .
- [3]. Bhagwati Charan Patel, Dr. G.R.Sinha (2010) An Adaptive K-means Clustering Algorithm for Breast Image Segmentation. International Journal of Computer Application in 2010 (0975 – 8887) Volume 10– N.4.
- [4]. H. Silverman , Md Facc, Mitchell S. Golbus, Md San Francisco Assessing Anatomy: Specific Techniques Echocardiographic Techniques for Assessing Normal and Abnormal Fetal Cardiac Anatomy Norman, California JACC Vol. 5, No. I January 1985:20S-9S.
- [5]. Irving Dindoyala, Tryphon Lambroua, Jing Denga, Cliff F Ruffb, Alf D Linneya, Andrew Todd-Pokropekaa n (UCL) and BUCL HospitalsNHS Trust (UCLH), UK. Level set segmentation of the foetal heart.
- [6]. Pedro F. Felzenszwalb, Ross B. Girshick, David McAllester and Deva Ramanan. Object Detection with Discriminatively Trained Part Based Models.
- [7]. Ted Scott, Hans Swan, Gerald Moran, Tapas Mondal, Judy Jones, Karm Guram and Jaime Huff, (2008)Increasing the Detection Rate of Normal Fetal Cardiac Structures: A Real-Time Approach, Journal of Diagnostic Medical Sonography 2008; 24; 63 originally published online Feb 21,2008.
- [8]. Timothy F. Cootes (2001), Gareth J. Edwards, and Christopher J. Taylor Active Appearance Models. IEEE Transactions on Pattern Analysis and Machine Intelligence, Vol. 23, no. 6, JUNE 2001 page No 681.
- [9]. Tuncer C. Aysal (2007)And Kenneth E. Barner(2007) Rayleigh-Maximum-Likelihood Filtering For Speckle Reduction Of Ultrasound Images IEEE Transactions On Medical Imaging, Vol. 26, No. 5.
- [10]. Sofia G. Antunes, José Silvestre Silva and Jaime B. Santos A New Level Set Based Segmentation Method for the Four Cardiac Chambers.
- [11]. S.Yagel, S.M.Cohen, I. Shapiro and D.V.Valsky 3D and 4D ultrasound in fetal cardiac scanning: a new look at the fetal heart Ultrasound Obstet Gynecol 2007; 29: 81–95 Published online in Wiley Inter Science (www.interscience.wiley.com). DOI: 10.1002/uog.3912